The Evolution of the Mastectomy at Georgetown

Lucy M. De La Cruz MD
System Lead For Breast Surgery Medstar
Chief of Breast Surgery Medstar/GUH
Associate Professor of Surgery Georgetown Medical School



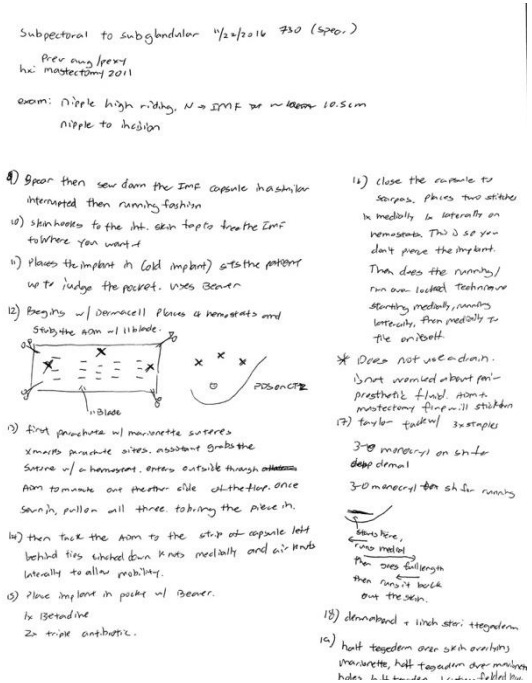

Subpectoral to subglandular 11/22/2016 730 (Spear)

Prev aug/pexy
hx: mastectomy 2011

exam: nipple high riding, N → IMF ~ 10.5cm
nipple to incision

9) Spear then sew down the IMF capsule in a similar interrupted then running fashion

10) skin hooks to the int. skin tap to free the IMF to where you want it

11) Places the implant in (old implant) sits the patient up to judge the pocket. Uses Beaver

12) Begins w/ Dermacell Places 4 hemostats and Stub the Aom w/ 11 blade.

13) first parachute w/ marionette sutures
x marks parachute sites. assistant grabs the suture w/ a hemostat. enters outside through Aom to mimic out the other side of the flap. once sewn in, pull on all three. tobring the piece in.

14) then tack the Aom to the strip of capsule left behind ties tinched down knots medially and air knots laterally to allow mobility.

15) Place implant in pocket w/ Beaver.
1x Betadine
2x triple antibiotic.

16) close the capsule to scarpas. Places two stitches 1x medially 1x laterally on hemostats. This is so you don't pierce the implant. Then does the running/run over locked technique starting medially, running laterally, then medially to tie on itself.

* Does not use a drain. Is not worried about peri-prosthetic fluid. Aom to mastectomy flap will stick down

17) taylor tack w/ 3x staples
3-0 monocryl on sh for deep dermal
3-0 monocryl ~~for~~ sh for running
starts here, runs medial then goes full length then runs it back out the skin.

18) dermabond + linch stori ttegederm

19) half tegederm over skin everything marionette, half tegederm over marionette holes half tegederm ...



Nipple-Sparing Mastectomy for Prophylactic and Therapeutic Indications

Scott L. Spear, M.D.
Shawna C. Willey, M.D.
Elizabeth D. Feldman, M.D.
Costanza Cocilovo, M.D.
Mary Sidawy, M.D.
Ali Al-Attar, M.D., Ph.D.
Catherine Hannan, M.D.
Laura Seiboth, M.D.
Maurice Y. Nahabedian, M.D.

Washington, D.C.

Background: Nipple-sparing mastectomy remains controversial and its adoption has been slow because of oncologic and surgical concerns.
Methods: A retrospective study evaluated all nipple-sparing mastectomies performed at a single institution for therapeutic or prophylactic indications for which records were available.
Results: Between 1989 and 2010, 162 nipple-sparing mastectomies were performed in 101 women. Forty-nine (30 percent) were performed for therapeutic purposes on 48 patients. A subareolar biopsy specimen was taken in 39 of 49 breasts (80 percent); four (10 percent) revealed ductal carcinoma in situ, and the nipple or nipple-areola complex was later removed. Four of 49 breasts (8 percent) in the therapeutic group had ischemic complications involving the nipple-areola complex, one of which (2 percent) was excised. With a mean follow-up of 2 years 6 months (range, 5 months to 9 years 5 months), no patients developed cancer in the nipple-areola complex. The remaining 113 mastectomies (70 percent) were performed prophylactically on 80 patients. The subareolar tissue was biopsied in 80 breasts (71 percent). One biopsy revealed lobular carcinoma in situ; none had ductal carcinoma in situ or invasive cancer. Two nipple-areola complexes (1.8 percent) were ischemic and excised. With a mean follow-up of 3 years 7 months (range, 5 months to 20 years 6 months), no patients developed new primary cancers in the nipple-areola complex.
Conclusions: Nipple-sparing mastectomy can be safe in properly selected patients. A subareolar biopsy can effectively identify nipple-areola complexes that may harbor cancerous cells. Ischemic complications resulting in nipple loss can ... at this technique deserves ... (*Plast. Reconstr. Surg.* 128: ... Therapeutic, IV.

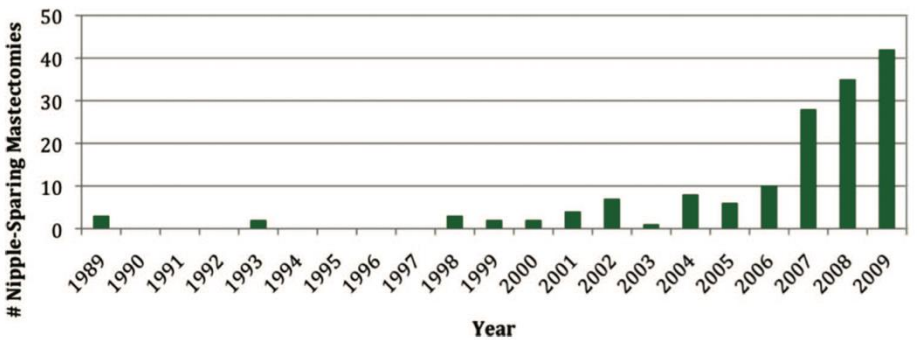

Fig. 2. Rising volume of nipple-sparing mastectomy at Georgetown University Hospital, 1989 to 2009.

2025 numbers

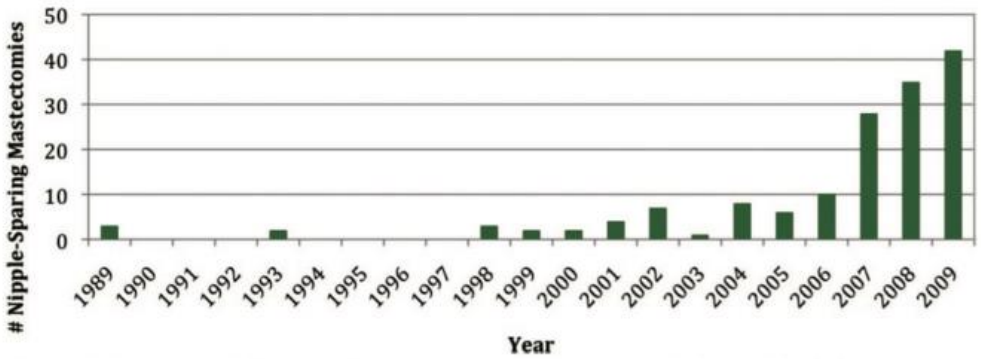

Fig. 2. Rising volume of nipple-sparing mastectomy at Georgetown University Hospital, 1989 to 2009.

Nipple-Sparing Mastectomy for Prophylactic and Therapeutic Indications

Scott L. Spear, M.D.
Shawna C. Willey, M.D.
Elizabeth D. Feldman, M.D.
Costanza Cocilovo, M.D.
Mary Sidawy, M.D.
Ali Al-Attar, M.D., Ph.D.
Catherine Hannan, M.D.
Laura Seiboth, M.D.
Maurice Y. Nahabedian, M.D.
Washington, D.C.

Background: Nipple-sparing mastectomy remains controversial and its adoption has been slow because of oncologic and surgical concerns.
Methods: A retrospective study evaluated all nipple-sparing mastectomies performed at a single institution for therapeutic or prophylactic indications for which records were available.
Results: Between 1989 and 2010, 162 nipple-sparing mastectomies were performed in 101 women. Forty-nine (30 percent) were performed for therapeutic purposes on 48 patients. A subareolar biopsy specimen was taken in 39 of 49 breasts (80 percent); four (10 percent) revealed ductal carcinoma in situ, and the nipple or nipple-areola complex was later
percent) in the therapeutic group had ischer
nipple-areola complex, one of which (2 perc
follow-up of 2 years 6 months (range, 5 months
developed cancer in the nipple-areola comple
mies (70 percent) were performed prophylac
areolar tissue was biopsied in 80 breasts (71
lobular carcinoma in situ; none had ductal carc
Two nipple-areola complexes (1.8 percent) we
mean follow-up of 3 years 7 months (range, 5 m
patients developed new primary cancers in the
Conclusions: Nipple-sparing mastectomy can
tients. A subareolar biopsy can effectively ident
may harbor cancerous cells. Ischemic complica
be minimized, and long-term follow-up sugge
further investigation in properly selected patie
1005, 2011.)
CLINICAL QUESTION/LEVEL OF EVIDEN(

4
THERAPEUTIC



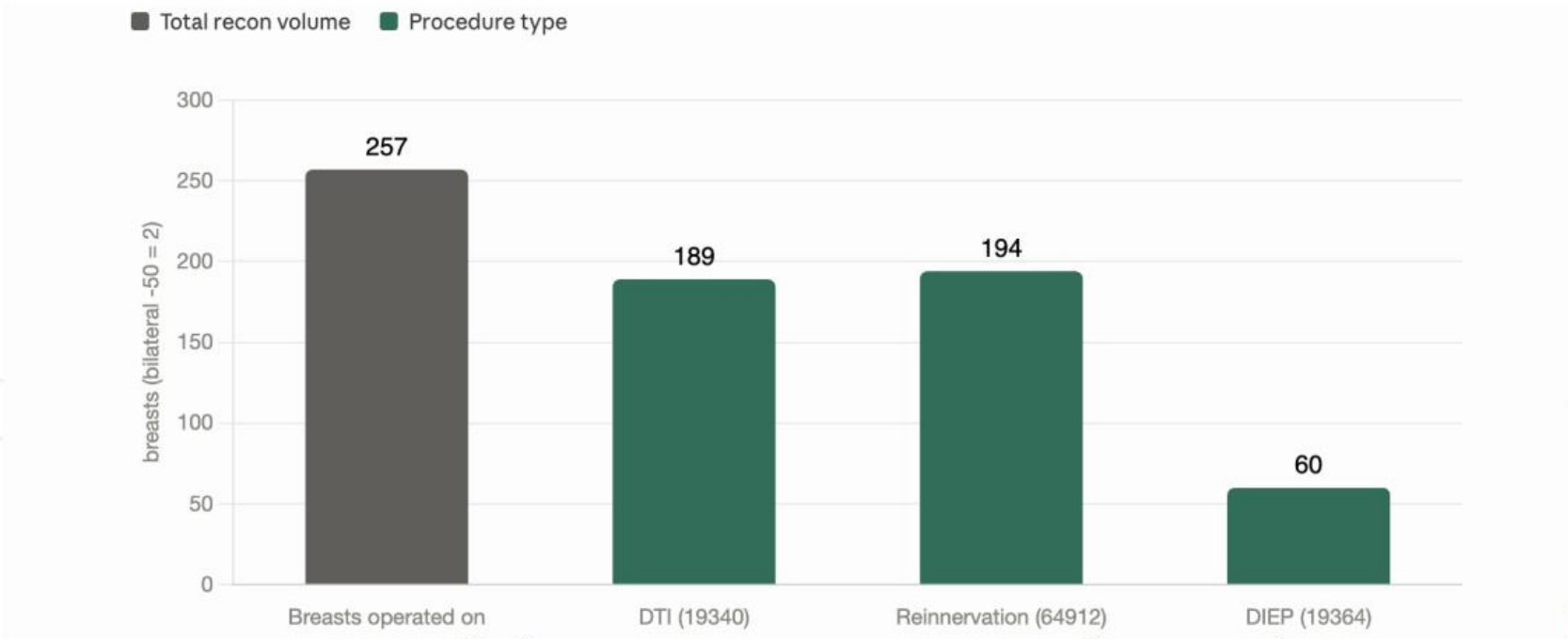

I on You

LITERATURE SELECTIONS

Nipple-Sparing Mastectomy Causes More Complications than Skin-Sparing after Breast Reconstruction

May 13, 2025

Nipple sparing mastectomy was performed in 36.4% of the cohort. The composite outcome was observed in 21.1% of the NSM group and 19.9% of the SSM group. After patient risk factor matching using multivariable statistical analysis, the risk of SSI and wound complications was found to be significantly higher in NSM group.



Olsen MA, Nickel KB, Margenthaler JA, et al. Nipple-Sparing Mastectomy and Infection Risk after Immediate Breast Reconstruction. *J Am Coll Surg*. 2025, in press.

Bayley EM. Nipple-Sparing Mastectomy, Informed Consent, and Shared Decision-Making. *J Am Coll Surg*. 2025, in press.

Nearly 40% of women who have mastectomy for treatment of breast cancer undergo immediate breast reconstruction with a breast implant or autologous tissue reconstruction. Skin sparing mastectomy (SSM) is the most common procedure, but there is increasing use of nipple-sparing mastectomy (NSM) to improve cosmetic outcomes.

Available evidence suggests that NSM is associated with an increased risk for wound complications leading to implant removal. This study sought to quantify the risk of surgical site infection (SSI) and overall wound complications in women (n = 352) who underwent mastectomy with immediate implant reconstruction. The primary outcome of interest was a composite of return to the operating room for treatment of a wound infection or wound complication during the first 180 postoperative days.

Nipple sparing mastectomy was performed in 36.4% of the cohort. The composite outcome was observed in 21.1% of the NSM group and 19.9% of the SSM group. After patient risk factor matching using multivariable statistical analysis, the risk of SSI and wound complications was found to be significantly higher in NSM group.

Structural (Open) Nipple-Sparing Mastectomy

STRUCTURAL NSM

Preserving the Circummammary Ligament in Nipple-Sparing Mastectomy

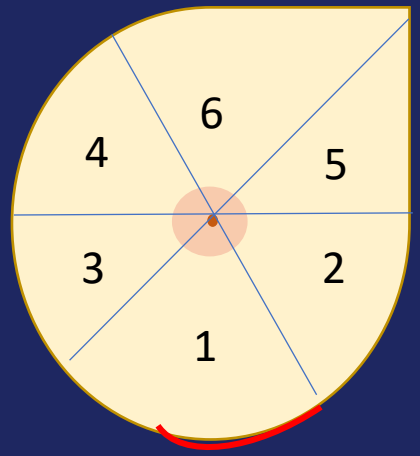

The Attachments of the Breast to the Chest Wall: A Dissection Study

Kathryn M. Gaskin, M.Phil.
Gregory E. Peoples, Ph.D.
Deirdre E. McGhee, Ph.D.
Wollongong, New South Wales, Australia

Background: The anatomical descriptions of the attachments of the female breast to the chest wall vary in their structure, location, and terminology within the published literature.
Methods: A dissection study of the attachments of the breast to the chest wall was conducted on 18 female embalmed breasts in the coronal (n = 15) and sagittal planes (n = 3).
Results: Perimeter, posterior wall, and horizontal septum attachments were observed. The perimeter along its entire length was attached to the chest wall. Regional and anatomical variation was observed in this structure and location.

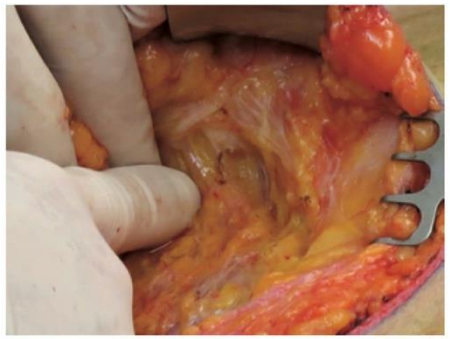

Fig. 6. Medial circummammary ligament carrying vessels, nerves, and lymphatics (higher magnification).

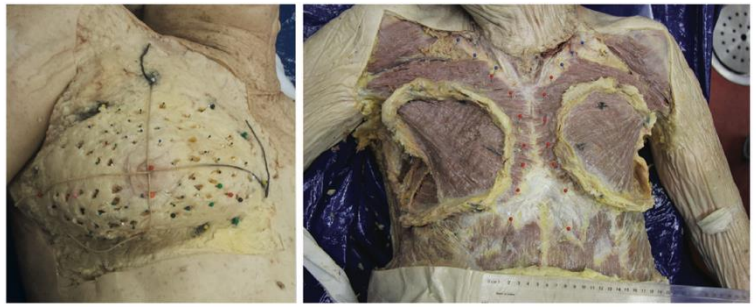

Fig. 2. (*Left*) Right breast of cadaver after sharp dissection to remove the adipose tissue from the complex three-dimensional fibroadipose pocket structure that encapsulated the corpus mammae. The perimeter of the breast is marked with ink dots and dressmaker pins along its circumference. The skin on the nipple-areola region is intact. (*Right*) Coronal view of the perimeter attachment of the breast to the chest wall. Ribs are marked with dressmaker pins.

Surgical Principles of the Structural Mastectomy

- 6 cm incision
- 6 zones
- Dissection on the breast capsule
- Tear drop shape breast
- Preservation of the circum-mammary ligament that contains nerves, vessels, and lymphatics

STRUCTURAL NSM

Preserving the Circummammary Ligament in Nipple-Sparing Mastectomy

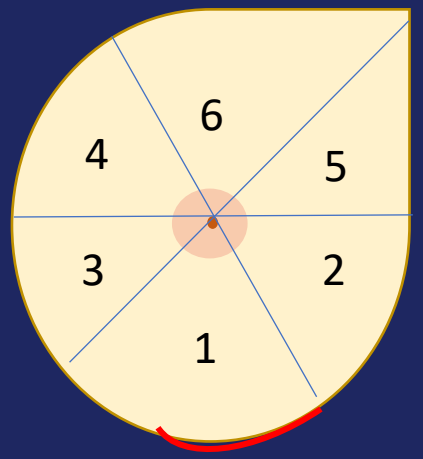

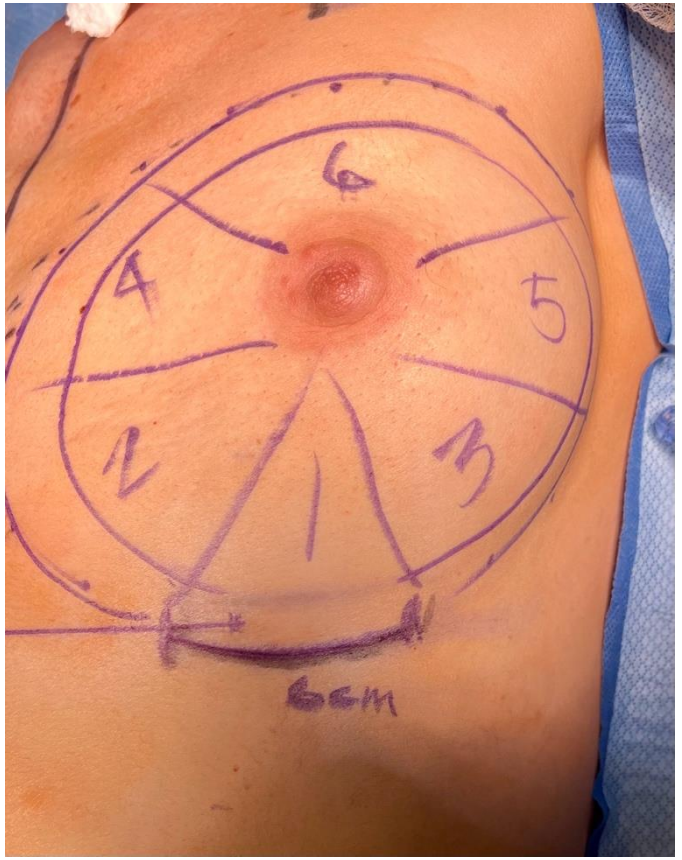

Surgical Principles of the Structural Mastectomy

- 6 cm incision
- 6 zones
- Dissection on the breast capsule
- Tear drop shape breast
- Preservation of the circum-mammary ligament that contains nerves, vessels, and lymphatics

STRUCTURAL NSM

Preserving the Circummammary Ligament in Nipple-Sparing Mastectomy

Retrospective cohort · 122 patients · 225 breasts Nov 2020–Jul 2024

STUDY GROUPS

90 **s-NSM breasts (40.0%)**
Structural technique

135 **Conventional NSM breasts (60.0%)**
Standard technique

s-NSM preserves the circummammary ligament, superficial fascial system, and adjacent perforators — rather than relying on blunt dissection through undefined planes.

Headline Reconstructive Results

s-NSM vs. conventional NSM, all breasts (n=225)

Table 3. Surgical Characteristics (by breast)

	Total	NSM	s-NSM	P-Value
	225 (100.0)	**135 (60.0)**	**90 (40.0)**	
OR Duration, min (median [IQR])	175 [84]	189 [108]	165 [50]	**0.002***
ADM Use	177 (78.7)	127 (94.1)	50 (55.6)	**<0.001***
Implant Volume, cc (median [IQR])	350 [160]	375 [165]	332.5 [175]	**0.018***
NAC Reinnervation	99 (40.0)	36 (26.7)	63 (70.0)	**<0.001***
Mastectomy Specimen Weight, g (median [IQR])	249 [203]	265.5 [191]	191 [159]	**0.002***
Lymph Node Dissection				0.174
None	138 (61.2)	78 (57.8)	60 (66.7)	
SLND	52 (23.1)	30 (22.2)	22 (24.4)	
ALND	13 (5.8)	10 (7.4)	3 (33.3)	
Both SLND and ALND	22 (9.8)	17 (12.6)	5 (5.6)	

Incision type was not well documented in charts

STRUCTURAL NSM

Preserving the Circummammary Ligament in Nipple-Sparing Mastectomy

Retrospective cohort · 122 patients · 225 breasts Nov 2020–Jul 2024

STUDY GROUPS

90 **s-NSM breasts (40.0%)**
Structural technique

135 **Conventional NSM breasts (60.0%)**
Standard technique

s-NSM preserves the circummammary ligament, superficial fascial system, and adjacent perforators — rather than relying on blunt dissection through undefined planes.

Headline Reconstructive Results

s-NSM vs. conventional NSM, all breasts (n=225)

Table 5. Reconstructive Outcomes.

	Total	NSM	s-NSM	P-Value
	225 (100.0)	**135 (60.0)**	**90 (40.0)**	
Short-Term Complications (≤30 days)				
Any Complication	32 (14.2)	27 (20.0)	5 (5.6)	**0.003***
Seroma	1 (0.4)	1 (0.7)	0 (0.0)	1.000
Hematoma	5 (2.2)	5 (3.7)	0 (0.0)	0.160
Dehiscence	1 (0.4)	1 (0.7)	0 (0.0)	1.000
Delayed Healing	9 (4.0)	7 (5.2)	2 (2.2)	0.321
Mastectomy Flap Necrosis	5 (2.2)	4 (3.0)	1 (1.1)	0.651
NAC Necrosis	15 (6.7)	14 (10.4)	1 (1.1)	
Partial Necrosis	12 (5.3)	11 (8.2)	1 (1.1)	**0.030***
Full Thickness Necrosis	3 (1.3)	3 (2.2)	0 (0.0)	0.277
NAC Removal Due to Necrosis	3 (1.3)	3 (2.2)	0 (0.0)	0.277
Cellulitis	2 (0.9)	2 (1.5)	0 (0.0)	0.518
Red Breast Syndrome	0 (0.0)	0 (0.0)	0 (0.0)	N/A
Surgical Site Infection	1 (0.4)	0 (0.0)	1 (1.1)	0.400
Nonelective Unplanned Return to OR for Complication	9 (4.0)	8 (5.9)	1 (1.1)	0.071
Reason for ROR (*out of ROR, n=9)				1.000
Hematoma Evacuation	3 (33.3)	3 (37.5)	0 (0.0)	
Tissue Necrosis Requiring Debridement	6 (66.6)	5 (62.5)	1 (100.0)	
Long-Term Complications (>30 days)				
Any Complication	17 (7.6)	15 (1.1)	2 (2.2)	**0.018***
Seroma	2 (0.9)	1 (0.7)	1 (1.1)	1.000
Hematoma	0 (0.0)	0 (0.0)	0 (0.0)	N/A
Dehiscence	3 (1.3)	3 (2.2)	0 (0.0)	0.277
Delayed Healing	6 (2.7)	5 (3.7)	1 (1.1)	0.406
Mastectomy Flap Necrosis	1 (0.4)	1 (0.7)	0 (0.0)	1.000
Partial NAC Necrosis	2 (0.9)	2 (1.5)	0 (0.0)	0.518
Cellulitis	3 (1.3)	2 (1.5)	1 (1.1)	1.000

STRUCTURAL NSM

Preserving the Circummammary Ligament in Nipple-Sparing Mastectomy

Retrospective cohort · 122 patients · 225 breasts Nov 2020–Jul 2024

STUDY GROUPS

90 **s-NSM breasts (40.0%)**
Structural technique

135 **Conventional NSM breasts (60.0%)**
Standard technique

s-NSM preserves the circummammary ligament, superficial fascial system, and adjacent perforators — rather than relying on blunt dissection through undefined planes.

Headline Reconstructive Results

s-NSM vs. conventional NSM, all breasts (n=225)

5.6% p = 0.003
vs. 20.0%
Acute complication rate (≤30 days)

1.1% p = 0.030
vs. 8.2%
Partial NAC necrosis

2.2% p = 0.011
vs. 11.9%
Delayed complication rate (>30 days)

3.3% p = 0.011
vs. 13.3%
Capsular contracture

Also: shorter OR time (165 vs. 189 min, p=0.002) • less ADM use (55.6% vs. 94.1%, p<0.001) • independently protective on multivariable analysis (OR 0.09, p=0.006, AUC 0.80)

Betty Lou Ourisman Breast Clinic — MedStar Georgetown University Hospital

Oncologic Safety Was Not Compromised

Therapeutic cases only (n=105) · median follow-up 2.3 years

Oncologic Outcomes — NSM vs. s-NSM

Outcome	NSM	s-NSM	p-value
Positive margins requiring re-excision	3.7%	**3.6%**	1.000
Local recurrence	6.1%	**0.0%**	0.294
Distant metastasis	9.1%	**0.0%**	0.082
Cancer-related death	5.3%	**0.0%**	0.107

No significant difference in margins, recurrence, metastasis, or death between groups. s-NSM cases skewed more ER/PR-positive and less triple-negative, and received less neo/adjuvant chemotherapy — a baseline imbalance to weigh alongside these results.

Bottom Line

Structural preservation of the circummammary ligament enables safe, single-stage prepectoral reconstruction — with fewer complications and less ADM — without an early signal of compromised cancer control.

Key Limitations

- Oncologic follow-up short (median 2.3 yrs) — findings preliminary
- s-NSM cohort skewed lower BMI/weight/implant volume; retrospective, single-institution
- Structural technique performed mainly by one surgeon; sensitivity analysis in that surgeon's own cases confirmed the complication and contracture findings

Preservation of the Circummammary Ligament in Nipple-Sparing Mastectomy with Direct-to-Implant Reconstruction is Associated with Improvement in Patient Outcomes

Table 5. Structural Nipple-Sparing Mastectomy BREAST-Q Scores Compared with Published Values (N=35 Patients)

Survey	s-NSM (N=35)	Normative Value	*p*-value	MROC DTI PROs at 1 year	*p*-value
Satisfaction with breasts	67.5 ± 16.4	58 ± 18	**0.002****	64.0 ± 16.8	0.216
Psychosocial well-being	75.9 ± 17.1	71 ± 18	0.097**	71.8 ± 19.0	0.162**
Physical well-being: chest	78.9 ± 13.7	93 ± 11	**<0.001****	76.7 ± 14.5	0.340
Sexual well-being[a]	57.3 ± 20.4	56 ± 18	0.997	53.0 ± 21.1	0.275**

Abbreviations: MROC, Mastectomy Reconstruction Outcomes Consortium Study; DTI, direct-to-implant; s-NSM, structural nipple-sparing mastectomy.

Bilateral NSM 6cm IMF incision, DTI, Reinnervation, no mesh

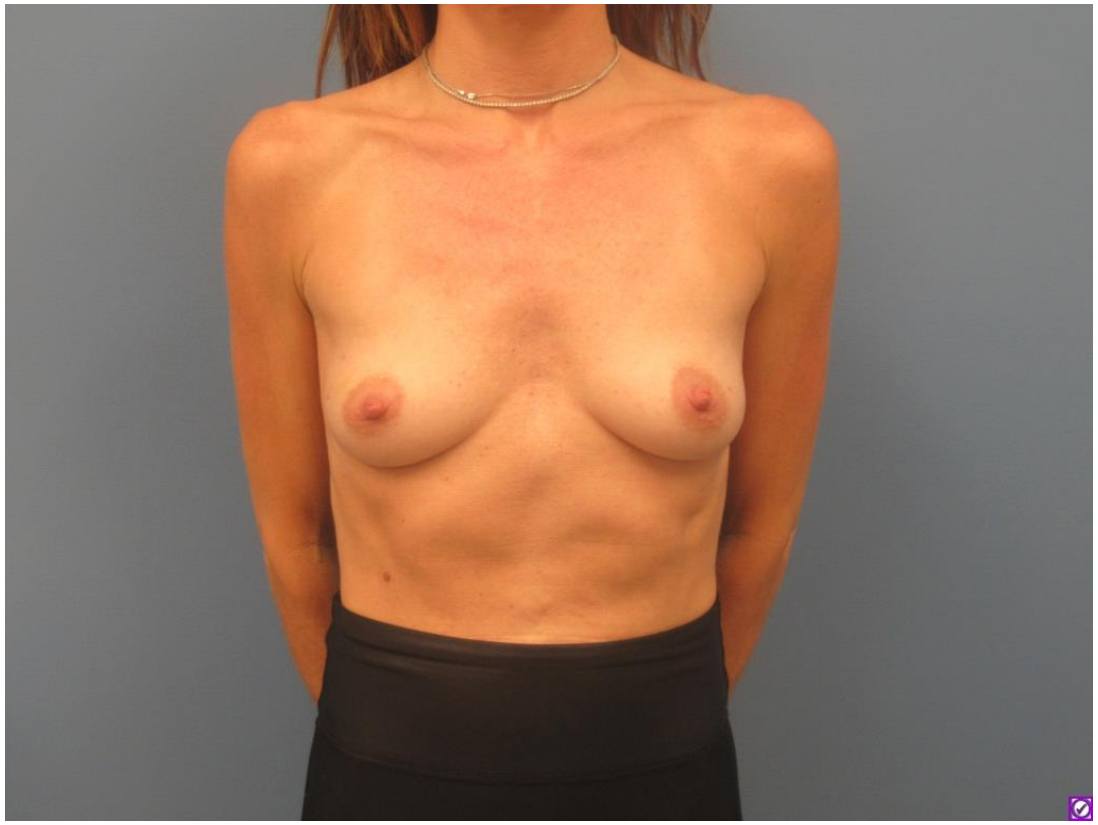

Pre-op

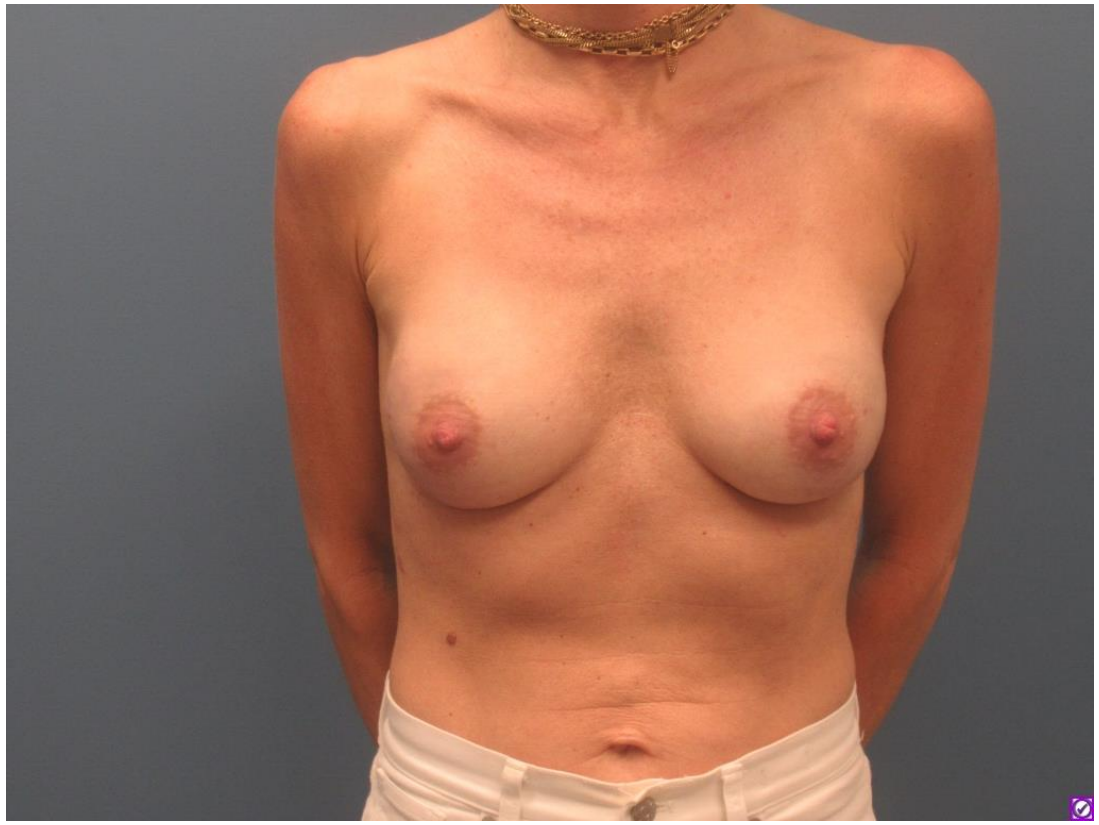

Post-op

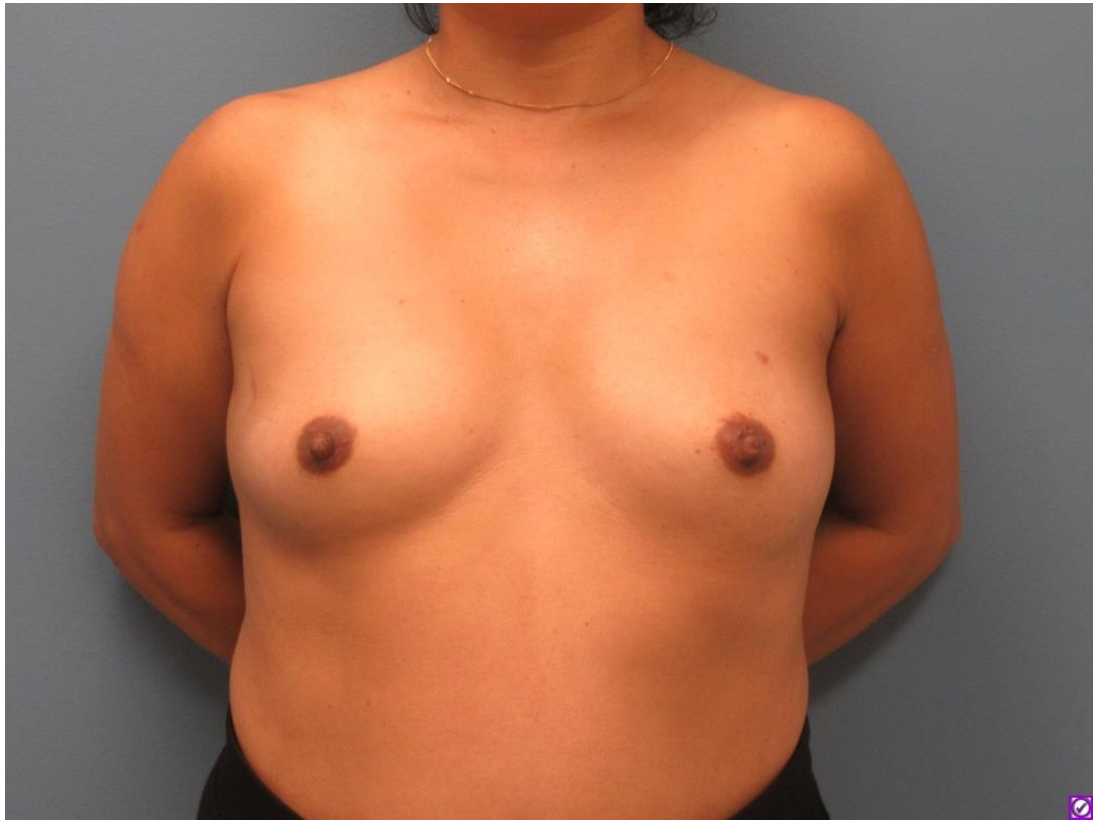

Pre-op



Post-op 1 month

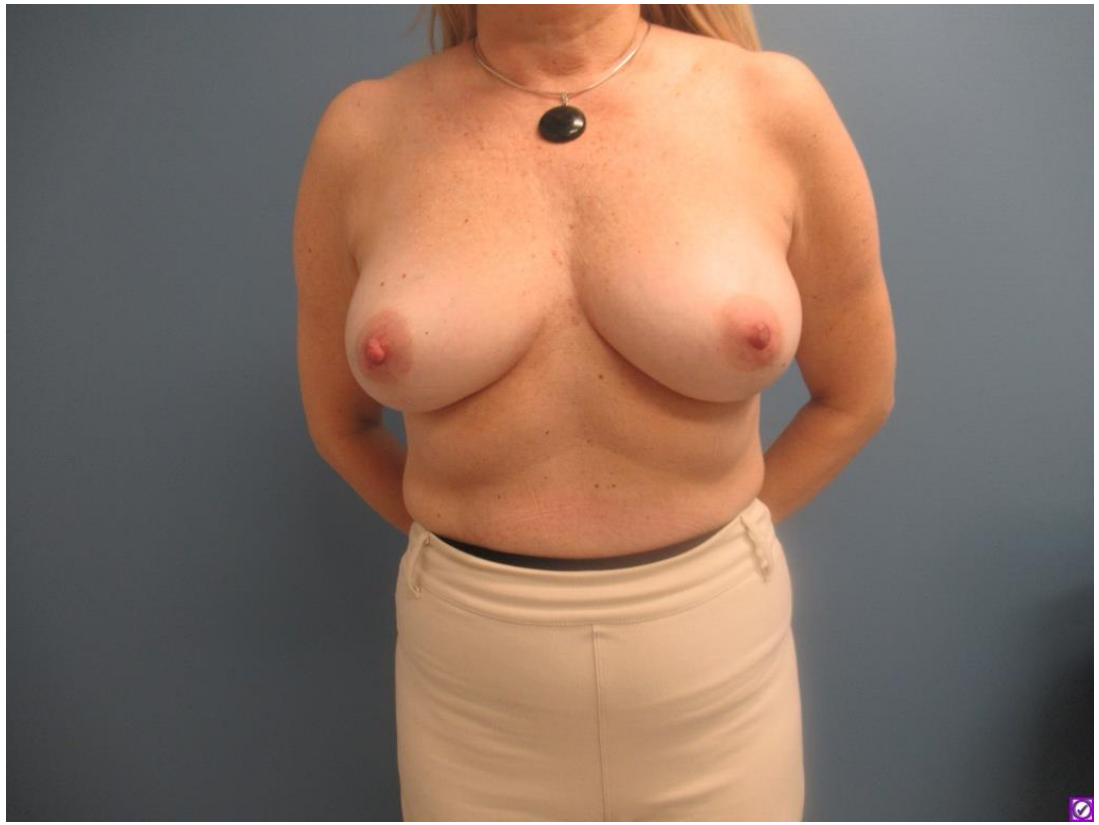

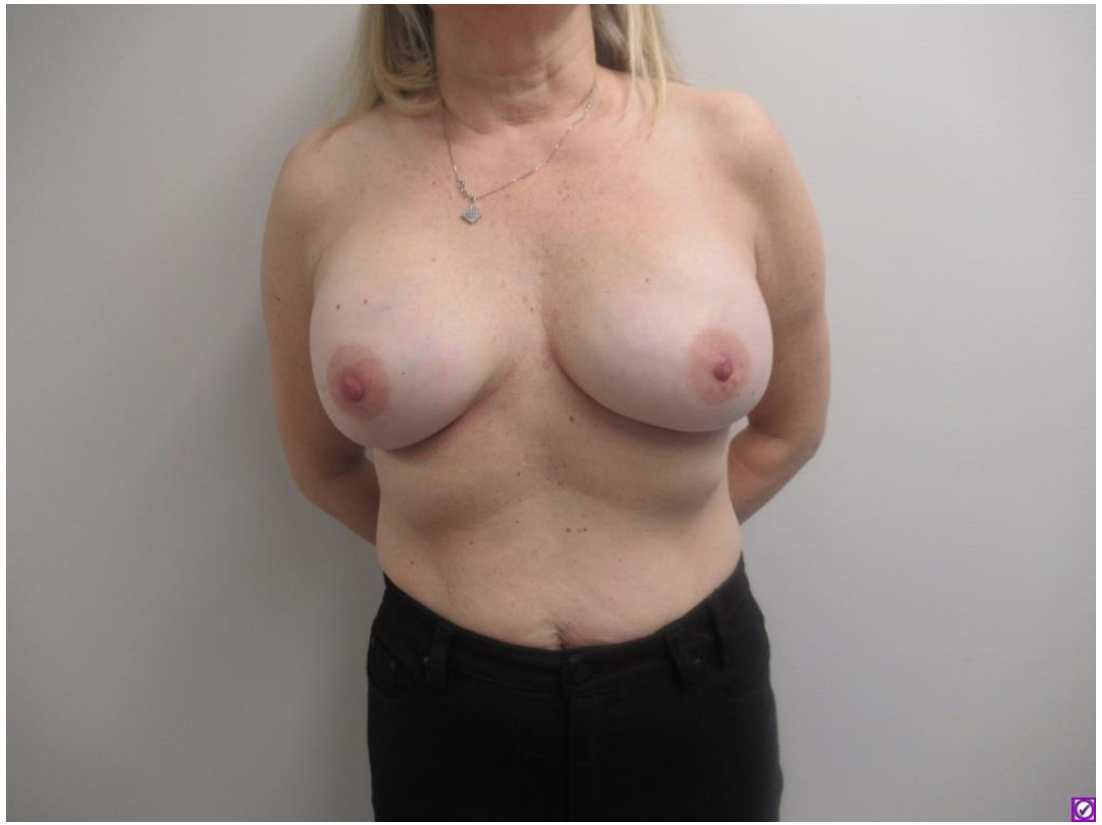

Pre-op

Post-op



Pre-op



Post-op 1 month

NSM with Lat flaps





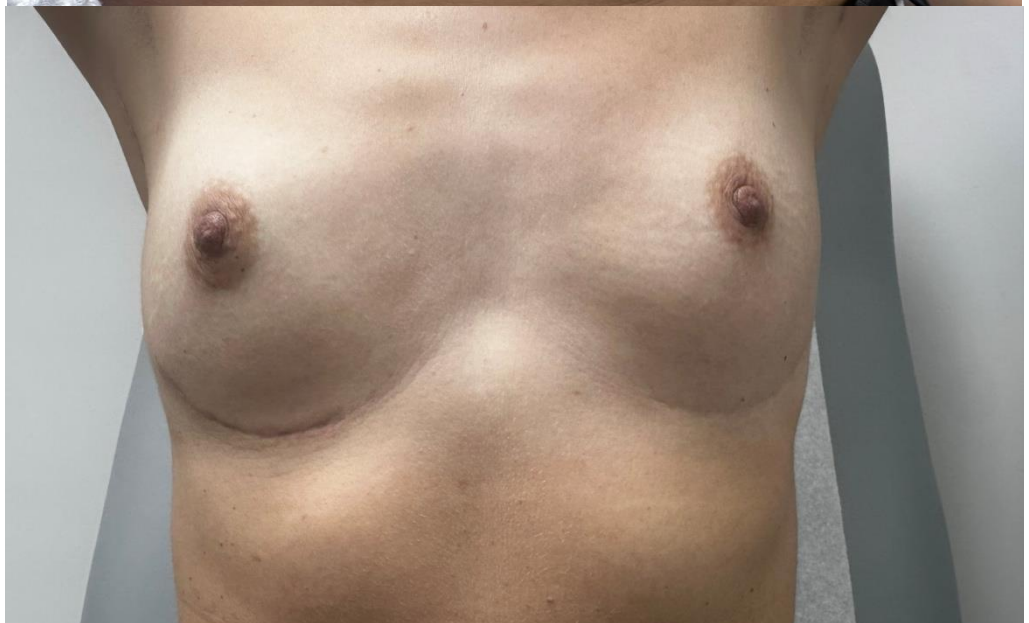

RIGHT NATURAL/ LEFT NSM W DIEP

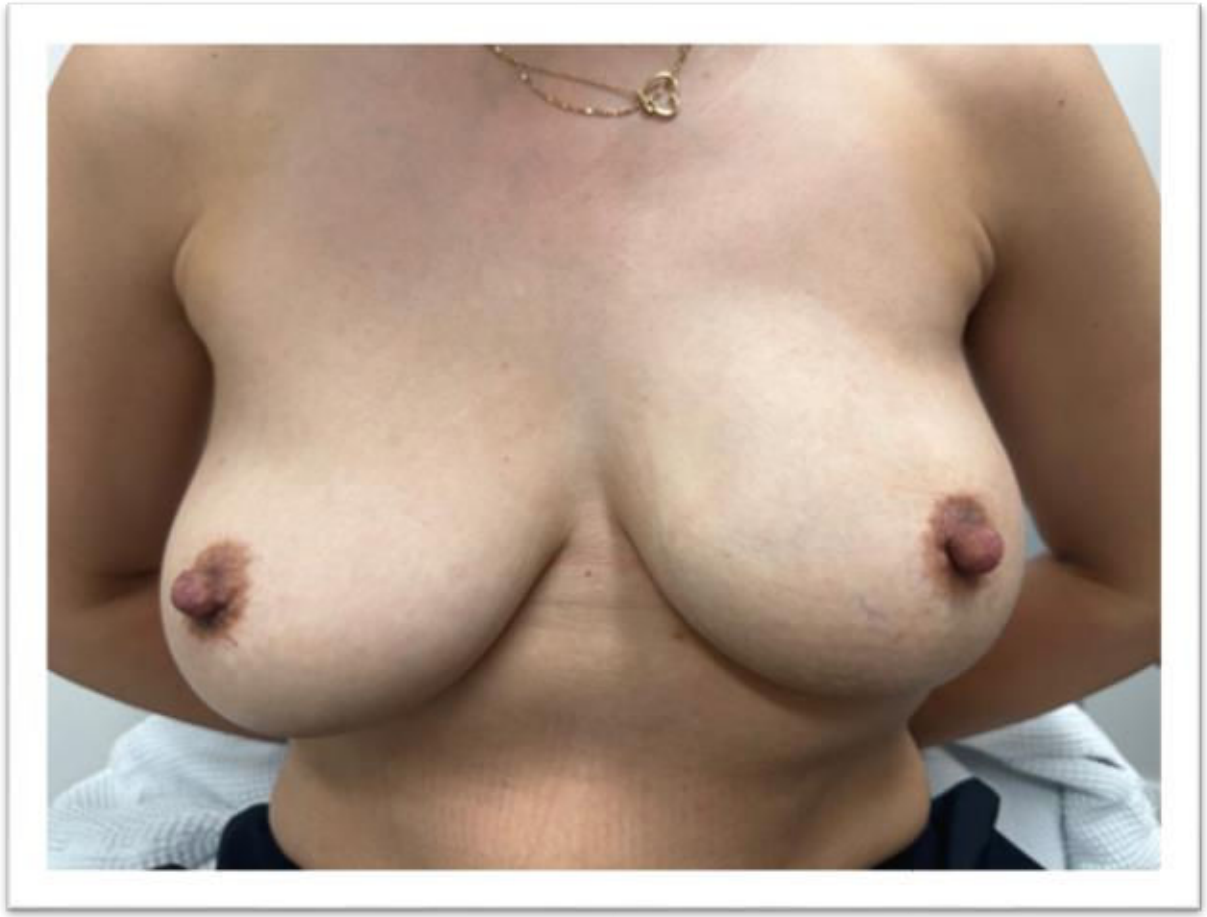







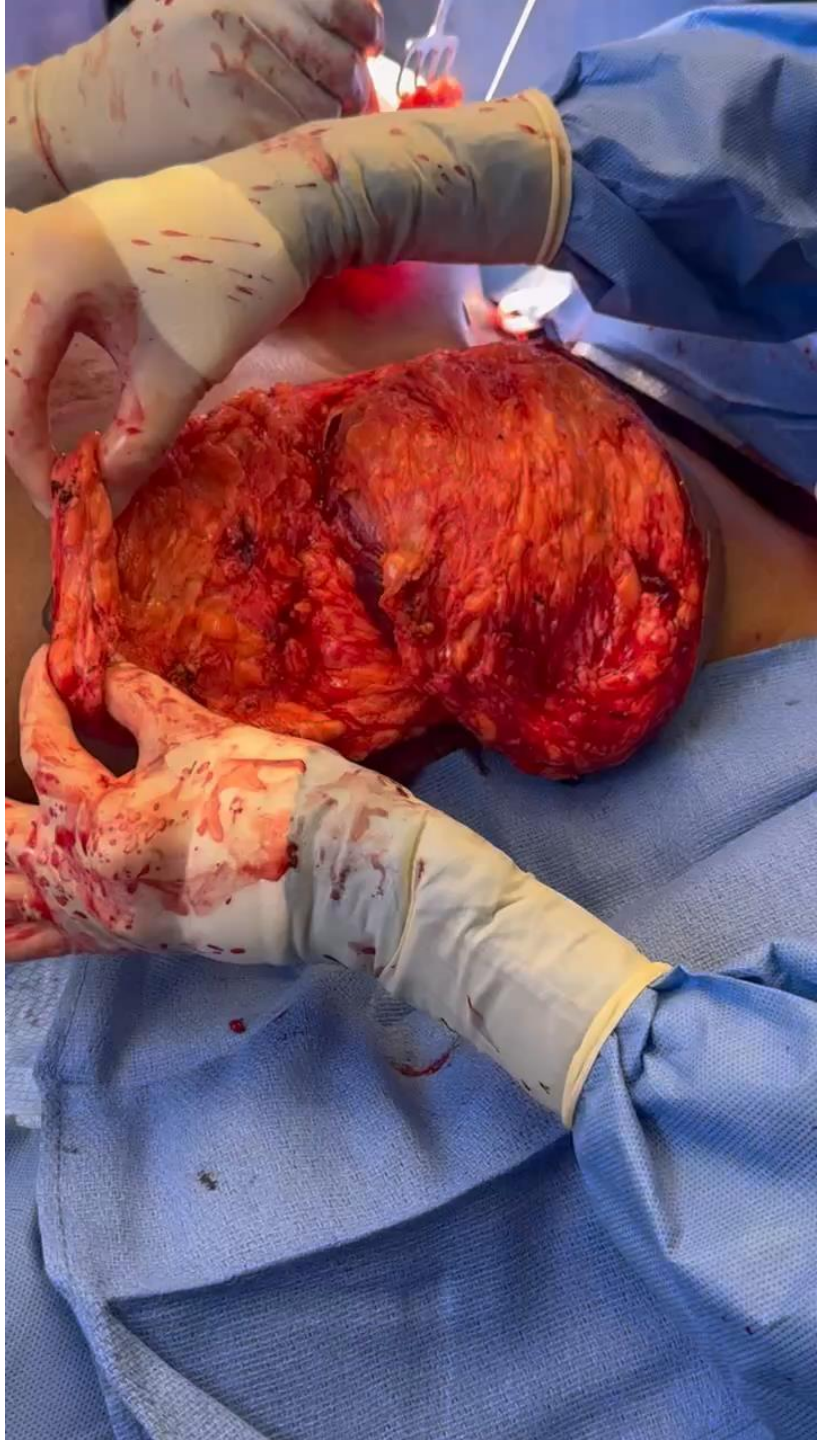



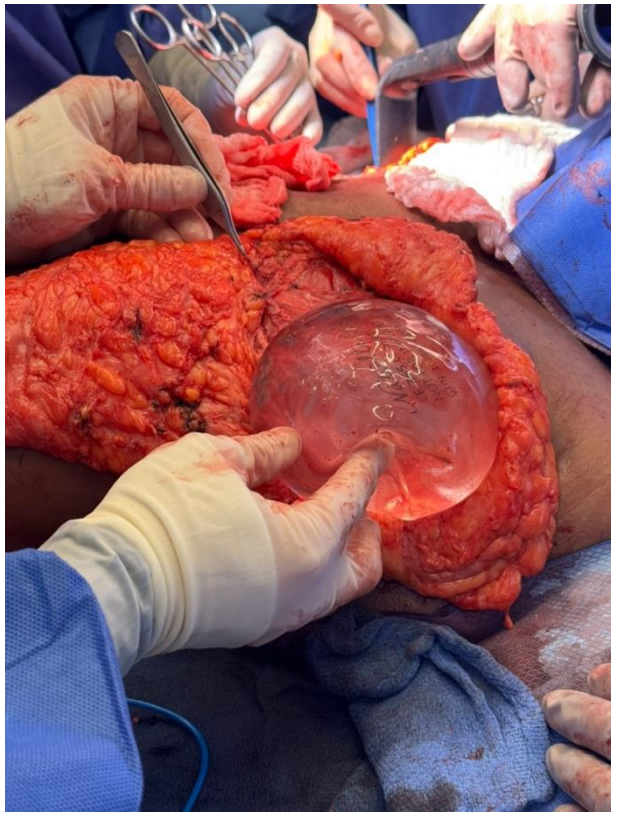

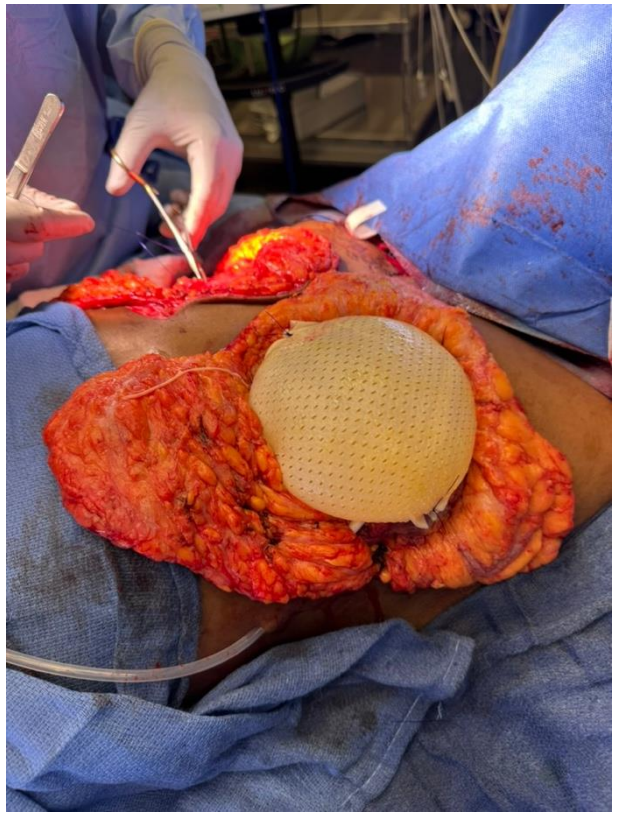

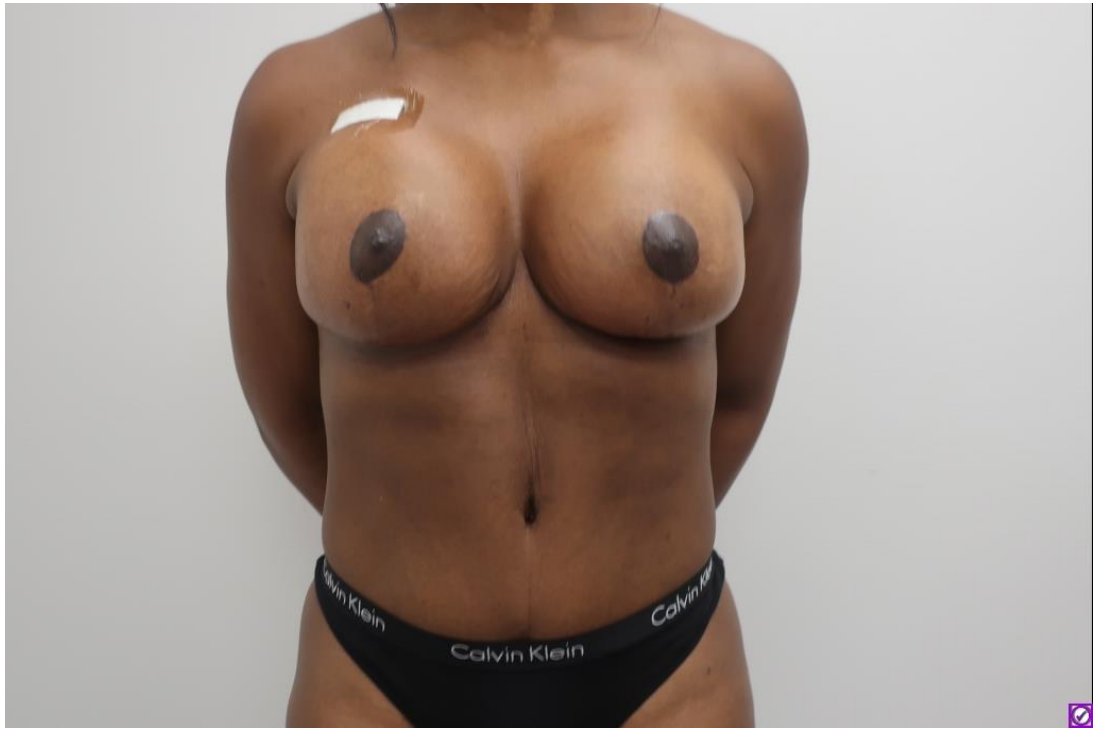

5 month postop
Allergan SCF-365

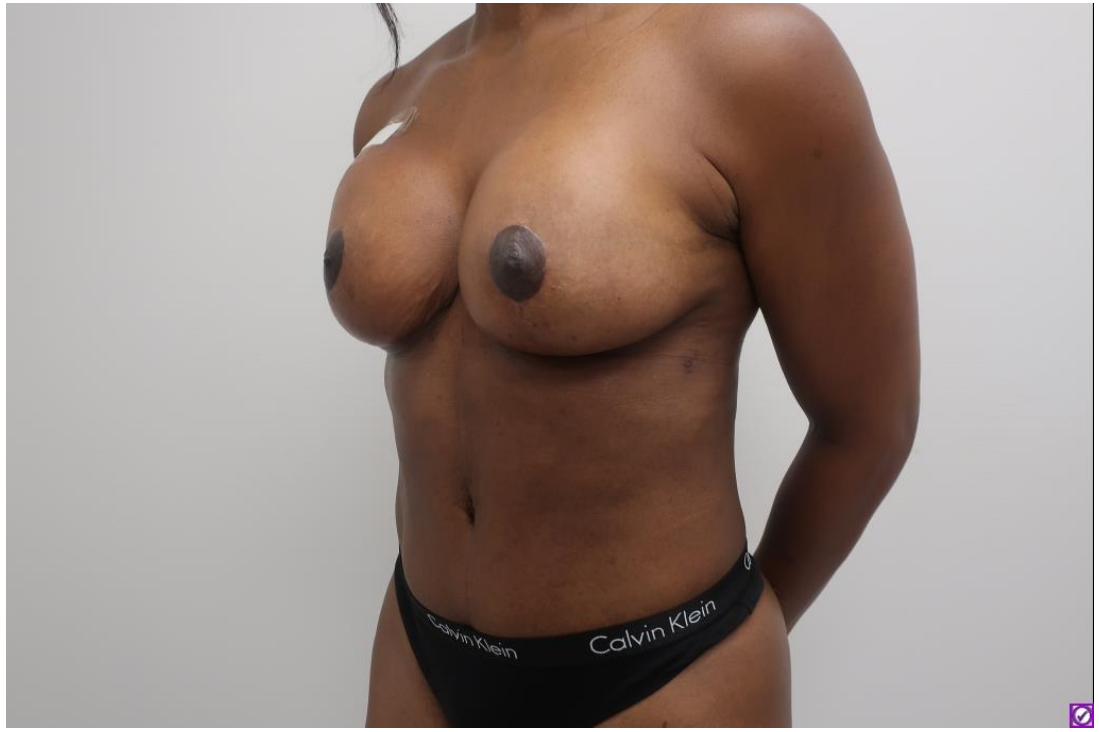

5 month postop

Wise Pattern NSM-Single Stage DTI







Wise Pattern NSM-Single Stage DTI





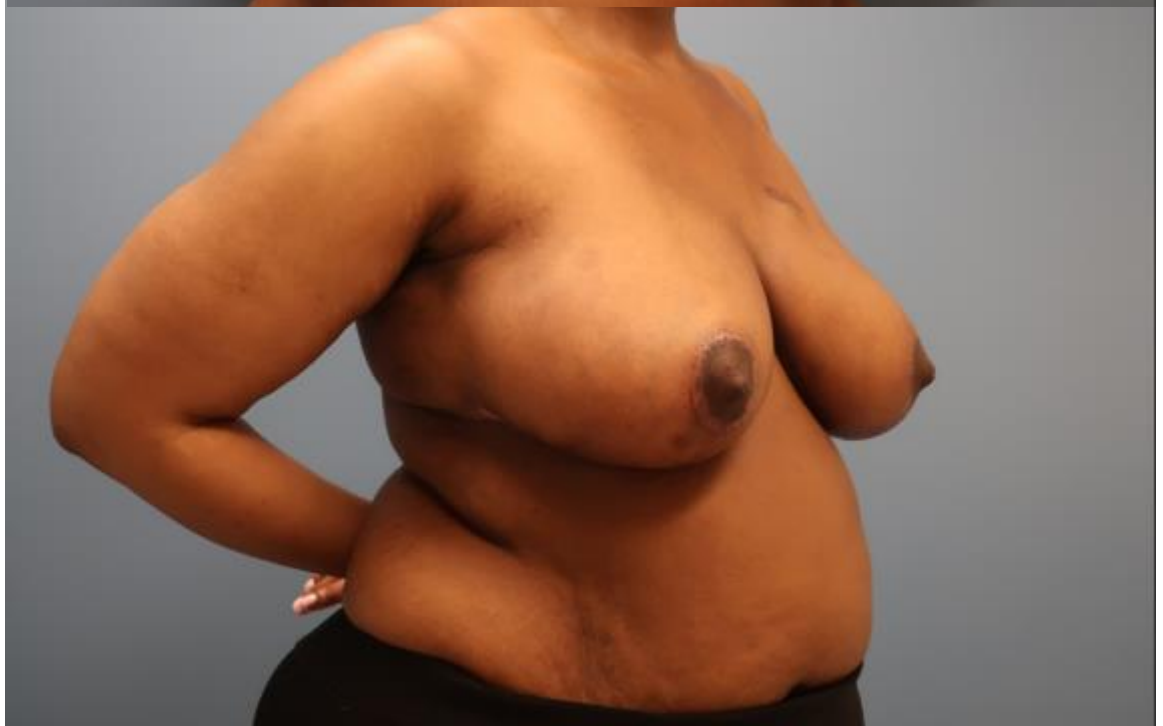

Cost Savings of $17,871 per structural mastectomy case compared with historic controls

A total of 126 patients were included, with 65 (51.6%) undergoing s-NSM and 61 (48.4%)

NSM. s-NSM was associated with:

1. Shorter operative time (168.6 ± 43.4 vs. 205.3 ± 74.1 minutes, $p<0.001$)
2. Fewer ADM sheets (0.83 ± 0.99 vs. 1.84 ± 0.55, $p<0.001$)

The total expected cost was lower in the s-NSM group ($27,037.08 s-NSM vs. $44,908.93 NSM)
QALYs were similar between groups (26.71333 s-NSM vs. 26.71296 NSM, difference 0.0004),

Bottom Line

Shorter OR times
Less ADM
Cost savings of $17,871 compared to historical Georgetown controls

Resensitization & Direct-to-Implant Reconstruction for ALL...

A combined single-stage pathway preserving both form and sensation

November 21, 2026

PRS Global Open
International Open Access Journal of the American Society of Plastic Surgeons

▸ Plast Reconstr Surg Glob Open. 2025 Mar 18;13(3):e6633. doi: 10.1097/GOX.0000000000006633

Direct-to-Implant in the Era of Prepectoral Breast Reconstruction: Evaluation of the National Trend in 59,313 Patients

Shahnur Ahmed *, Jackson A Baril *, Carla S Fisher †, Rachel M Danforth *, Ravinder Bamba *, Mary E Lester *, Aladdin H Hassanein *,✉

▸ Author information ▸ Article notes ▸ Copyright and License information

PMCID: PMC11918641 PMID: 40104386

Annual Frequency of TE Reconstruction and DTI Reconstruction

	Years													
	2010	2011	2012	2013	2014	2015	2016	2017	2018	2019	2020	2021	2022	Total
N	2474	2528	3455	4133	3045	4459	5326	5509	5365	5413	5412	5732	5427	59,313
TE	2249 (90.9%)	2246 (88.8%)	2983 (86.3%)	3485 (84.7%)	3453 (87.5%)	3866 (86.7%)	4528 (86.5%)	4702 (85.4%)	4392 (81.8%)	4241 (78.3%)	4319 (79.8%)	4519 (78.8%)	4268 (78.6%)	49,466
DTI	225 (9.1%)	282 (11.2%)	472 (13.7%)	628 (15.3%)	492 (12.5%)	593 (13.3%)	708 (13.5%)	807 (14.6%)	973 (18.1%)	1172 (21.6%)	1093 (20.2%)	1213 (21.2%)	1159 (21.4%)	98[illegible]

Feedback

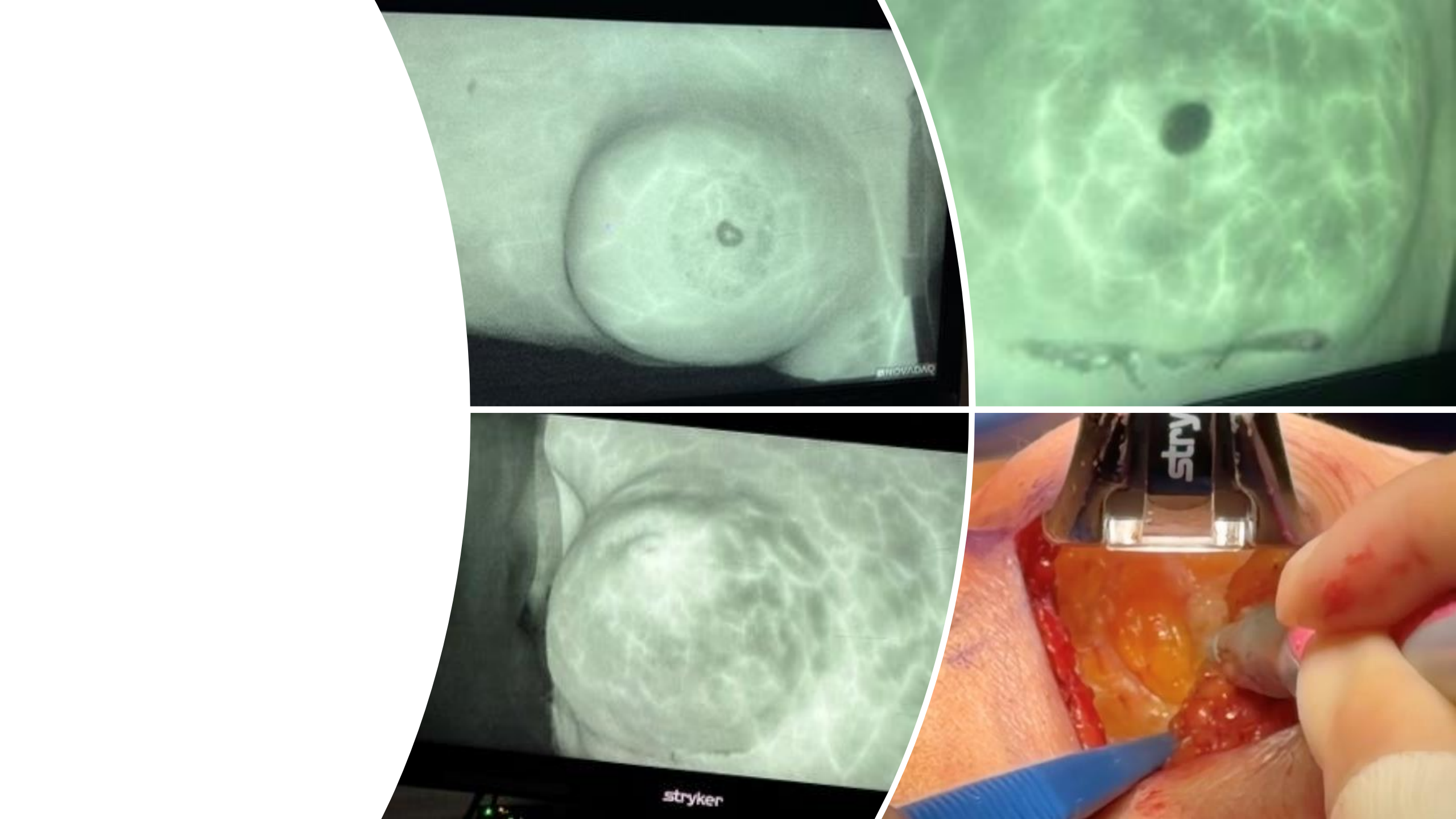
stryker

One Operation, Two Goals

Restoring breast form and breast sensation in a single, coordinated surgical pathway at the time of mastectomy.

1 Direct-to-Implant Reconstruction

- Definitive **implant placed at the time of mastectomy** — no tissue expander, no second staged reconstructive surgery.
- Single-stage approach **reduces total number of operations** and overall recovery time for the patient.
- Requires careful patient selection: mastectomy flap quality, breast size/ptosis, and oncologic factors.

+

2 Resensitization

- **Nerve allograft technique** coapts sensory nerves **at the time of mastectomy** to preserve/restore breast and nipple sensation.
- **Addresses a long-underrecognized quality-of-life gap** — postmastectomy numbness — without adding a separate operation.
- Offered as standard of care to **100%** of our NSM patients.

Sensory Outcomes

CENTRAL NAC RECOVERY OVER TIME

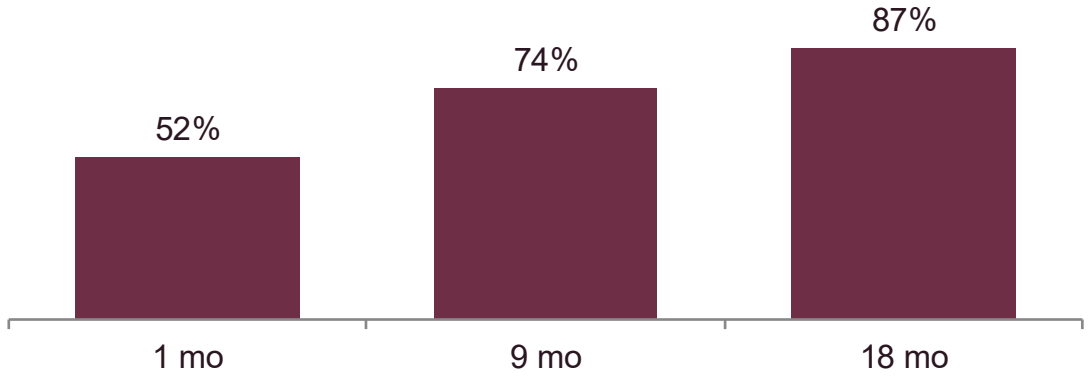

OR 1.11–1.13 per month (p = 0.001–0.007) — sensation improves significantly with time since surgery.

INDEPENDENT PREDICTORS OF LOWER RECOVERY

Higher BMI	**OR 0.63–0.66 / 1-SD**
Greater resection weight	**OR 0.70 / 1-SD (~124 g)**
Larger implant size	**OR 0.63–0.66 / 1-SD**

Not significant: chemotherapy, radiation, prior breast surgery, steroid use, ADM/mesh, two-staged mastectomy, nerve coaptation count, drain duration.

RECOVERY BY BREAST ZONE (ODDS VS. CENTRAL NAC)

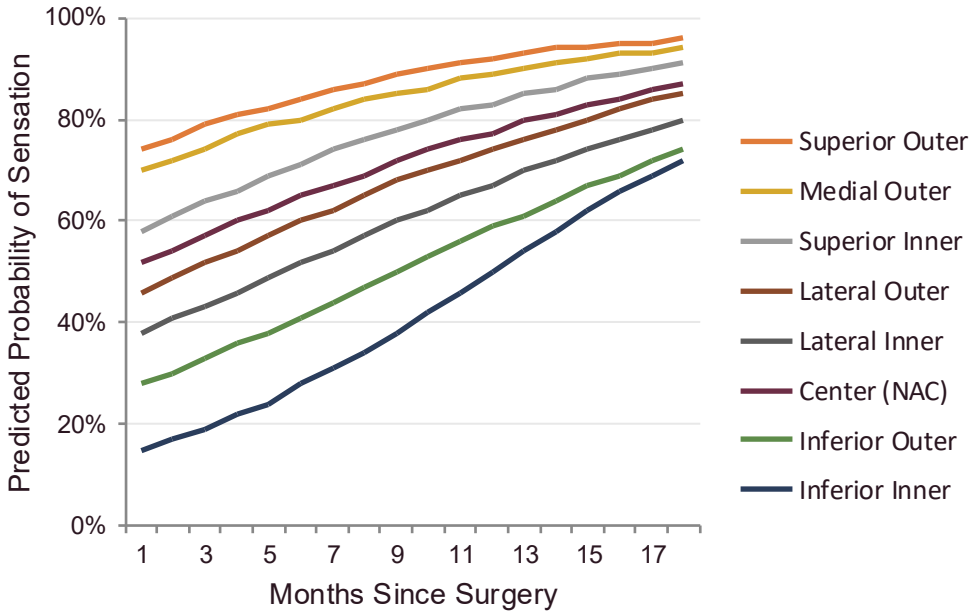

Inferior Inner zone: 19% recovery at 3 months → 50% at 12 months — slowest-recovering zone throughout follow-up.

Bottom line: Breast volume — not chemo, radiation, or nerve technique — drives most variability in sensory recovery, useful for preoperative counseling.

GEE logistic mixed model, 936 zone-level readings from 86 breasts, random intercept per breast (σ = 1.23). Tables 4–6.

PROGRAM CONTEXT

A High-Volume Foundation in Nipple-Sparing Mastectomy set the stage for the FUTURE...

~250	97%	<1%	100%
open NSM cases performed annually	of mastectomy practice is nipple-sparing and DTI	nipple/skin necrosis rate	of NSM patients offered resenzitisation surgery

This foundation — built on a clinical and research identity in NSM dating to 1989 — is the platform from which our robotic and endoscopic programs launched in 2026.

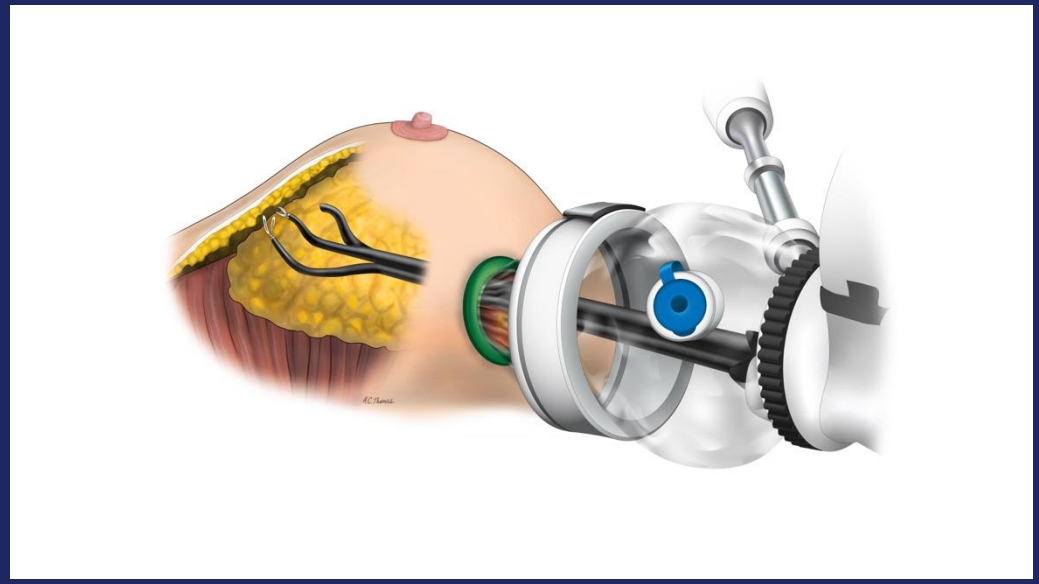

Robotic Nipple-Sparing Mastectomy

A single-port approach through a single inframammary fold incision

Incision Location in Robotic vs Endoscopic Nipple-Sparing Mastectomy: Published Series

Table 1. Robotic-assisted nipple-sparing mastectomy (R-NSM): incision location and axillary access

Series (first author, journal, year)	Platform	n	Incision location	Incision length	Axillary staging route
Toesca and early multiport series (summarized in Kopkash et al., Journal of Surgical Oncology, 2020)	da Vinci Si / Xi	Early series	Axilla, ± second port	2.5–4 cm (+ 0.8-cm port)	Through axillary incision
Park HS et al., Scientific Reports, 2019	da Vinci Si / Xi	Initial experience	Longitudinal, anterior axillary line below axillary fossa	3.5–6 cm	SLNB done manually through same incision
Go J et al., Journal of Surgical Oncology, 2022	da Vinci SP	81	Bra line at nipple level, anterior to midaxillary line	Median 40 mm (20–55)	SLNB through lateral incision before docking
Lai HW et al., World Journal of Surgical	Various	460-case comparison (R-NSM subset)	Single axillary or lateral chest	Not specified	Same incision
Farr DE et al., JAMA Surgery, 2024	da Vinci SP	20 patients / 40 breasts	Lower hair-bearing axilla	Not specified	SLNB (60%) in pre-docking phase, same incision
Lee SB et al., Scientific Reports, 2025	da Vinci SP	60	Mid- or anterior axillary line (100%)	4–5 cm	SLNB / ALND through mastectomy incision
Kuo WL et al. (RASPB-1), Scientific Reports, 2026	da Vinci SP + SP Access Port	Pilot trial	Vertical, midaxillary line	3–5 cm	Axillary procedure first, same incision
Kopkash K, Piltin M et al. (multicenter RCT), Annals of Surgical Oncology, 2026	da Vinci SP	14 US sites	Not specified in abstract (verify in full text)	—	—
Present series (our institution)	[Platform]	15 patients / 30 breasts	**Inframammary fold**	**4 cm**	**SLNB through same IMF incision; no axillary incision**

Approach	Predominant incision	Evolution	IMF used as primary access?
Open (conventional) NSM	IMF (37.8% of 9,975 NSMs; Daar et al., Plastic and Reconstructive Surgery, 2019) or radial	IMF independently protective of overall complications (Frey et al., Plastic and Reconstructive Surgery, 2018)	Yes, but usually needs a separate axillary incision for nodal staging
Endoscopic NSM	Single axillary / lateral	Periareolar + axillary, then multi-port, then single axillary / single-port (Kopkash et al., Journal of	No published series identified; one series starts a lateral incision at the

Approach	Predominant incision	Evolution	IMF used as primary access?
		Surgical Oncology, 2020)	IMF (Yu et al., 2024)
Robotic NSM	Single axillary / lateral chest / bra line, 2.5–6 cm	Multiport (Si/Xi) to single-port (SP)	No published series identified; mentioned only as a theoretical option (Kim JH et al., JAMA Surgery, 2024)
Present series	**4-cm IMF, robotic docking + SLNB through same incision**	—	**Yes**

The Single-Port Technique

Approach

- Single robotic port placed via a single **incision** along the **inframammary fold** — avoiding visible scarring on the breast mound.
- Robotic optics and instrumentation enable mastectomy flap dissection under magnified, stable visualization through a minimal-access incision.
- Designed to preserve the nipple-areolar complex while minimizing the visible surgical footprint compared to open NSM incisions.

14

robotic single-port NSM cases performed to date

Program Milestone

Among the earliest reported single-port robotic NSM experiences and the **ONLY PROGRAM IN THE WORLD USING** a **single inframammary fold incision WITH ALL 4 PROCEDURES**, building directly on our high-volume open NSM foundation.

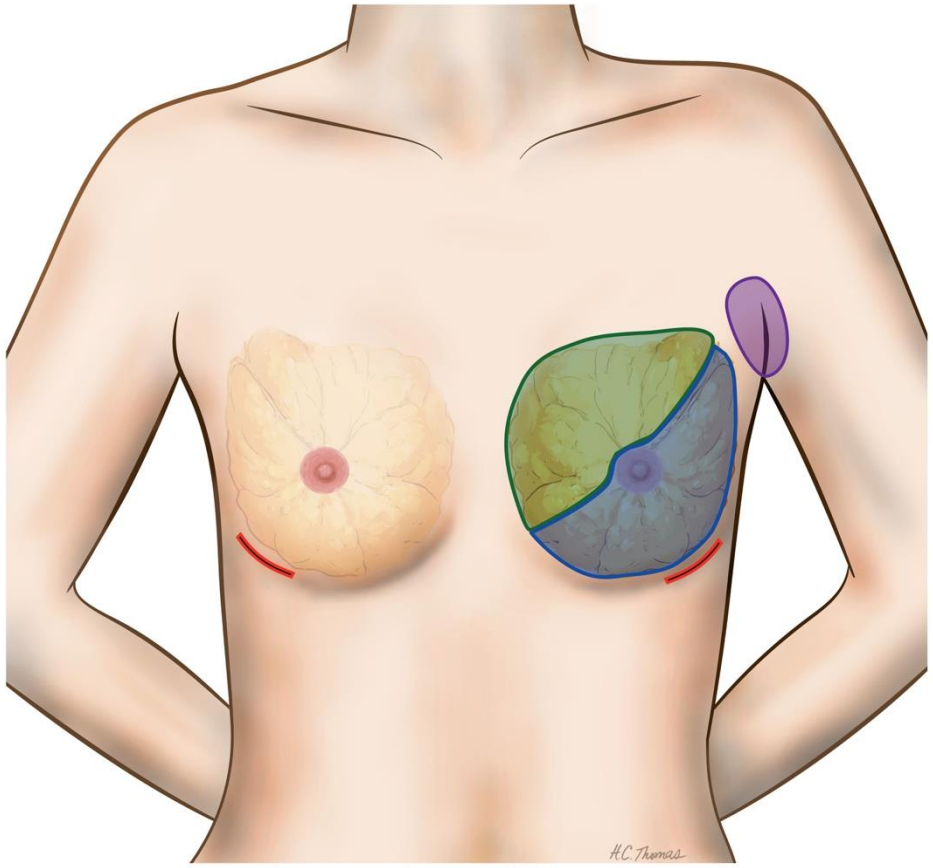

4 cm Inferolateral Incision

Removed Robotically

Removed via Manual Dissection

Area of Lymph Node Dissection

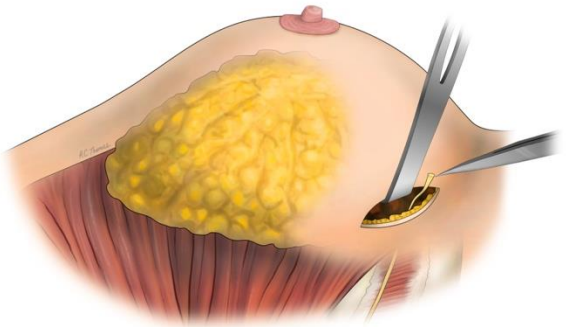

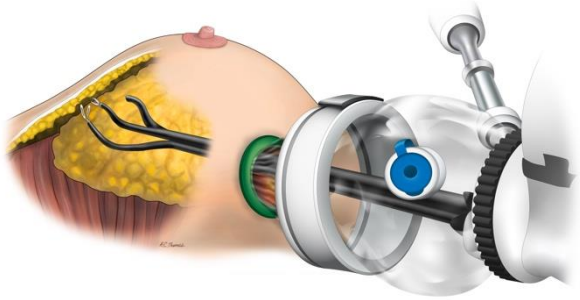

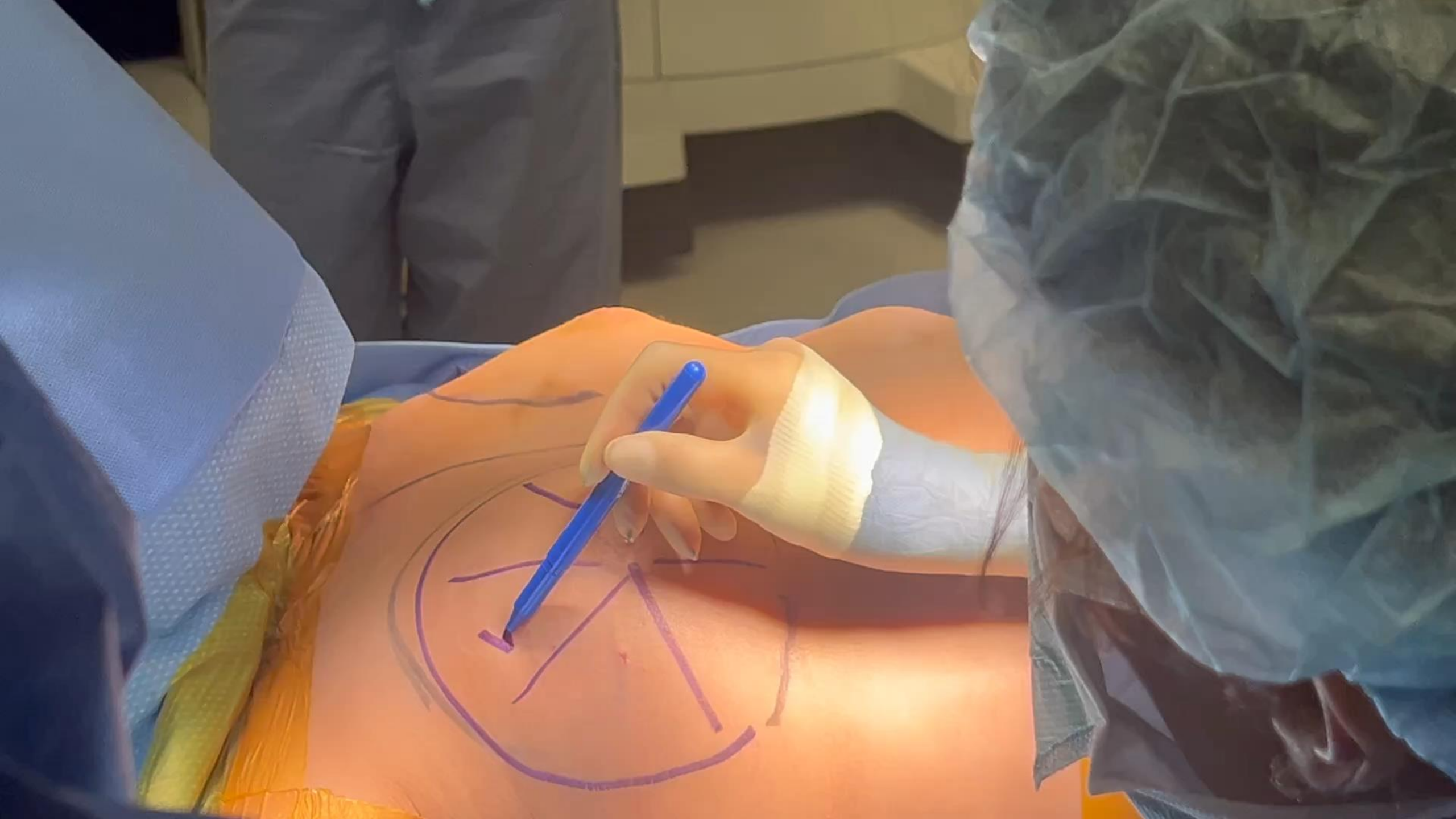



Pre-operative



Post-operative Day 12





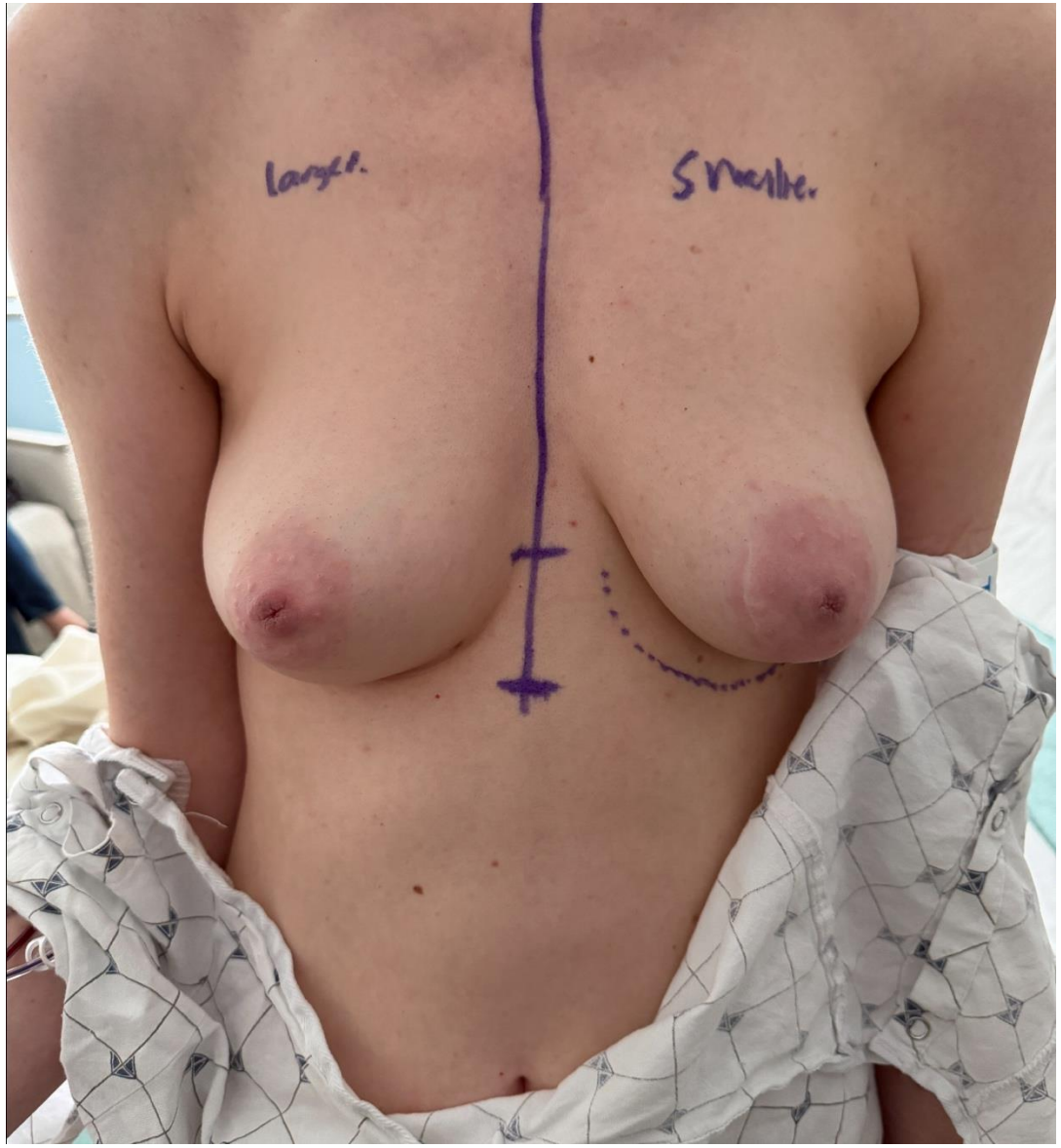
Smaller.



Thank You

Questions & Discussion